

Lameness Control in Dairy Herds

Part 3 - White Line Lesions

Nick Bell MA, VetMB, PhD, MRCVS

White line lesion is the second most common claw disease affecting dairy cattle, with 5.5 cases per 100 cows per year recorded as the average treatment rate in the UK¹. The average case is thought to cost approximately £193, costing the average farm over £1000 per year per 100 cows. However, in some herds white line can become a major problem with over 30 cases per 100 cows per year costing approximately £5800 per 100 cows per year.

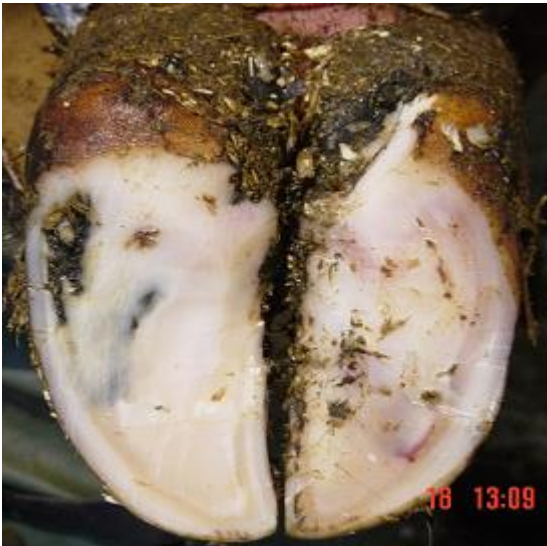

Fig 1: A typical white line lesion in the heel of an outer hind claw

Causes

The white line is the soft, white horn that joins the wall horn with the sole horn. It is produced by the laminae which means any disturbance to the laminae, such as bruising, will produce even weaker horn. As the white line joins the hard capsule of wall horn with the relatively flexible sole horn, it has to withstand considerable tensions. These tensions are increased by with turning and pushing behaviour on hard surfaces, or sharp, stony penetrations from the environment. Wet conditions can soften the horn and increase the risk.

The main factors thought to contribute to white line lesions include:

- Rumen acidosis and other dietary imbalances leading to poor horn quality
- Physical trauma producing bruised white line horn
- Shearing forces across the white line, such as twisting and turning on an unyielding surfaces
- Loose stone and uneven surfaces that physically penetrate the white line

When the white line lesion extends as far as the quick, a site of infection can become established, often resulting in an abscess if the drainage is blocked. Alternatively, a lower grade focus of inflammation or infection may be present, producing a mild lameness.

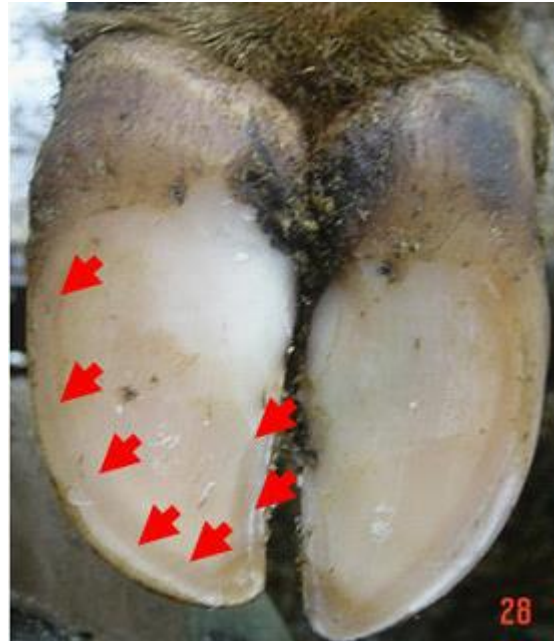


Fig 2: a picture with arrows showing the white line, the paler horn that connects the sole with the wall horn.



Fig 3: the white line horn is deposited as the wall slides down the folds of laminae from the coronary band to the sole. A weakness often occurs between each of the laminae. This is visible as railway line markings on the white line where dirt penetrates the weaknesses. These weaknesses allow the white line to split right up into the laminae. A seat of infection can then establish high up the wall, as seen in this claw.

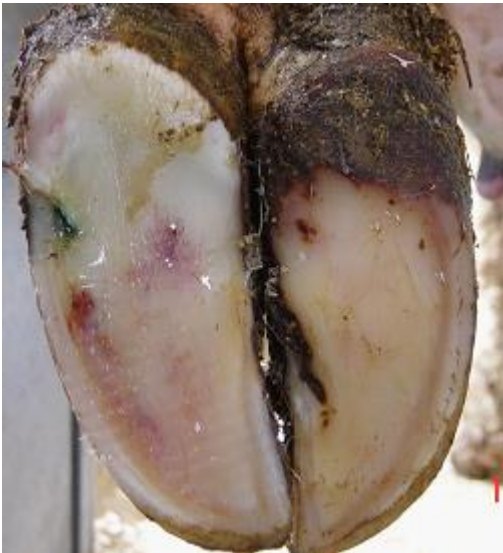80% of white line lameness cases occur in the outer claw of the hind feet, mostly in the heel and outer side of the claw, reflecting the poorer claw horn and increased exposure to physical forces in this claw.

Treatment

Dutch 5 step method foot trimming should be performed, which will help identify the site of the white line lesion or lesions. Animals exhibiting signs of moderate to severe lameness are likely to have an abscess.



Fig 4 (above and below): -Many white line abscess form at the base of very fine tracts in the white line. Treatment involves removal of the wall horn to create a drainage route for the pus



case, then in most instances all the under-run horn has to be removed. When a deep and chronic infection of the quick in the wall has become established (wall ulcer) the veterinary advice should be requested as these take many months of intense treatment to correct.

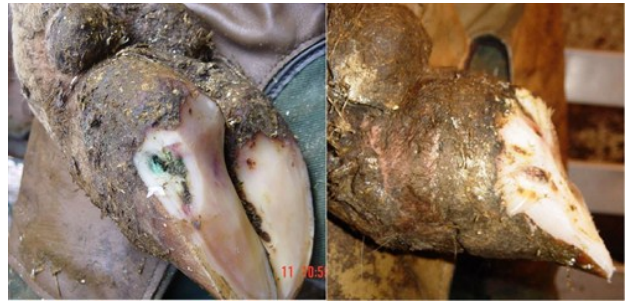

Fig 5a & b (above and above right) After 7-14 days the swelling of the quick will have reduced allowing the under-run horn to be completely removed without risk of creating a wall ulcer. If this under-run horn is left, then slurry and moisture will be trapped next to the quick, encouraging chronic infection

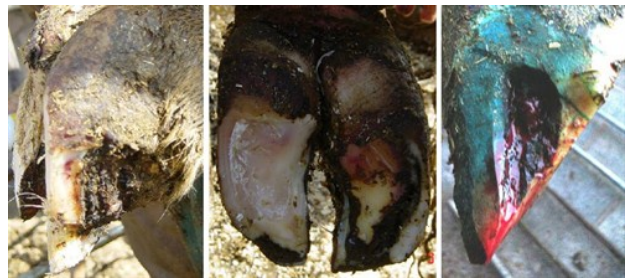


Fig 6: If left untreated, white line infections have a tendency to track up the wall (left image) or under the sole to the heel (centre image). In these cases the under-run horn needs removing to allow recovery. If the quick becomes chronically infected then wall ulcers tend to form (right image), which take many months to resolve.

Once the likely white line lesion is identified, it should be opened by removing the wall, starting at the sole surface, using a very sharp knife, being careful not to cut into the quick (see Figures below). If there is an abscess, this will lead to the sudden release of pus. A large drainage hole should be made and weight relieved onto the opposite claw. While it may be argued that bearing weight will help express pus, what happens in practice is that the cow avoids bearing weight and slurry contaminates the drainage hole. A bandage and poultice for one day can help draw pus. If significant improvement is not seen within 24 hours then the track will need to be re-explored to create better drainage. Flushing with dilute antiseptic can aid recover, and good hygiene will always help. Cows that have had an abscess invariably benefit from further trimming within 1-2 weeks. Most cases do not require antibiotics.

1-2 weeks following a white line abscess the extent of the under-run horn can be seen. The quick will be less swollen, and more easily avoided with the knife. The loose horn can be completely removed to avoid a chronic infection becoming established.

When white line abscesses have been missed, they either burst out the coronary band or run under the sole and burst out the back of the heel. If that is the

To summarise, the principles of white line lesion treatment involve:

- Careful identification of the painful lesion
- Good drainage of any pus
- Relieve weight from the painful claw
- Removal of any loose or under-run horn (often 1-2 weeks later)

Prevention of white line lesions

Prevention of white line lesions involves reducing standing times and improving the diet, cow flow and under-foot surfaces. Step 5 of the Dutch 5 step claw trimming method will help remove early lesions that haven't progressed to the laminae.

white line by up to 50% and may also increase milk yield, partly or fully off-setting the cost.

Supplementation needs to be maintained long-term and the beneficial effects will only be noticeable after approximately 130 days.

reduced lying behaviour, the increased risk of bruising and risk of twisting on concrete

- Pushing in collecting yard - improve collecting yard design to ensure good flow; encourage cows into the parlour, never shout or drive cows; disarm the electric backing gate, taking up slack space with the backing gate and no more; avoid any aversive experiences.

- Turning on the parlour exit - improve dispersal and cover rough concrete with rubber matting.
- Bullying in the housing - create cross passages, open up blind ending alleys, create extra space to reducing stocking density, address sources of bullying.

prevent stone penetrations. Laying a base that drains well (1 in 20 camber with sun and wind drying), is compacted with a 70 tonne roller and is well maintained will help.



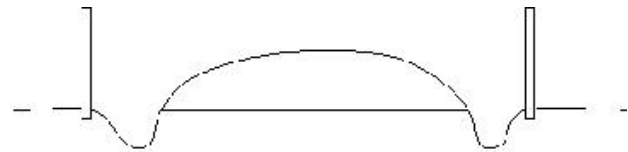
Fig 7: A misaligned heifer against a backing gate can be a risk for white line injuries. On this farm gentle use of the backing gate and rubber floor matting reduces the negative impact of this.



Fig 8: Out-of-parlour feeders are common places for cow bullying.



Fig 9: - Above is a picture of an oolitic limestone track. This material crushes to a fine material and self-stabilises. This can be achieved with hard stones and builders rubble (metal removed) by finely crushing, adding cement and compacting. Soft stone (limestone or sandstone) crumble rather than penetrate the white line. Similarly, pine peelings or wood chip prove very comfortable for cows, provided they are well drained. Achieving good drainage by raising the track, creating a camber to ditches and encouraging drying appears to be most important for lameness prevention. Other practical issues include regular maintenance including the removal of mud verges that form over time.



NADIS seeks to ensure that the information contained within this document is accurate at the time of printing. However, subject to the operation of law NADIS accepts no liability for loss, damage or injury howsoever caused or suffered directly or indirectly in relation to information and opinions contained in or omitted from this document.

To see the full range of NADIS livestock health bulletins please visit www.nadis.org.uk